

Explanation of Surveillance/Diagnostic Algorithms for Hepatocellular Carcinoma (Figure 1)

1. Initiating surveillance

The decision of whether to initiate surveillance begins with patient risk assessment. Patients with hepatitis B, hepatitis C, or cirrhosis are considered to fall within the high-risk group. In addition, screening test intervals are determined with consideration of risk factors such as age, sex, presence or absence of diabetes mellitus, BMI, AST, ALT, platelet number, alcohol consumption, and HBV-DNA levels (for chronic hepatitis B patients). Among these risk factors, hepatitis B cirrhosis and hepatitis C cirrhosis are considered as extremely high-risk factors.

2. Surveillance

There is no clear evidence indicating the optimum timing of surveillance. The drawbacks of a shorter screening interval are related to cost. The lower the risk, the higher the costs are for finding a single cancer patient. It is suggested that ultrasound be performed once every 3–4 months for extremely high-risk patients and once every 6 months for high-risk patients. In terms of tumor marker testing, it is recommended that AFP, AFP-L3 fractions, and PIVKA-II (=DCP) be measured once every 3–4 months for extremely high-risk patients and once every 6 months for high-risk patients. Currently, as of 2013, monthly measurements of AFP and PIVKA-II are covered by insurance in the aforementioned extremely high-risk and high-risk groups. However, the AFP-L3 fraction can be measured only when there is a strong reason to suspect hepatocellular carcinoma.

3. Nodular lesions indicated on ultrasound

If new nodular lesions are indicated on ultrasound, dynamic CT or dynamic MRI is performed and a differential diagnosis is obtained. Contrast-enhanced ultrasound may be considered for patients with renal impairment or allergies to contrast media of CT/MRI. In some patients, CT/MRI can be used if nodules cannot be observed because of poor ultrasound visualization.

4. Diagnosis by dynamic CT or dynamic MRI

4.1 Contrast enhancement in the early phase

Typical hepatocellular carcinoma is defined as a nodule(s) seen as a high-density area in the arterial phase and a low-density area (washed out) in the portal venous and equilibrium phases compared with the surrounding liver parenchyma. If typical findings are present, the lesion should be treated as hepatocellular carcinoma. If early-phase contrast enhancement is observed without delayed-phase washout, and if the diameter of the tumor is 1 cm or lesser, the patient should be monitored every 3 months. For tumors larger than 1 cm in diameter, tests such as Gd-EOB-DTPA-enhanced MRI, contrast-enhanced ultrasound, CT angiography, and liver tumor biopsy should be considered. If the lesions can be visualized on ultrasound, follow-up monitoring should be performed using ultrasonography; however, if the lesions cannot be visualized on ultrasound, dynamic CT or dynamic MRI should be performed at the follow-up. If tumor size increases during ultrasound monitoring, dynamic CT or dynamic MRI should be repeated.

4-2 No contrast enhancement in the early phase

If contrast enhancement is not observed in the early phase on dynamic CT/MRI, and if the tumor diameter is 1.5 cm or lesser, the patient should be monitored every 3 months. If the tumor is larger than 1.5 cm in diameter, tests such as Gd-EOB-DTPA-enhanced MRI, contrast-enhanced ultrasound, CT angiography, and liver tumor biopsy should be considered. The method of patient monitoring is the same as that described in 4-1.

4-3 Atypical imaging findings

If there is a reason to strongly suspect intrahepatic cholangiocarcinoma, metastatic liver cancer, or benign liver tumors based on the enhancement patterns in the arterial and portal venous/equilibrium phases, further testing should be performed for each possibility.

5. Elevated tumor marker levels

If AFP levels are persistently elevated or 200 ng/mL or higher, if PIVKA-II levels are elevated to 40 mAU/mL or higher, or if the AFP-L3 fraction increases to 15% or higher, dynamic CT or

dynamic MRI should be considered, even if tumors are not detectable on ultrasound.

6. Optional testing

Hepatocyte-specific contrast-enhanced MRI (Gd-EOB-DTPA-enhanced MRI, SPIO-enhanced MRI, etc.), CT angiography, and liver tumor biopsy are optional tests that may be performed at the physician's discretion for further examination.

Figure 1: Surveillance algorithm/diagnostic algorithm for hepatocellular carcinoma (separate file)

Explanation of the Treatment Algorithm for Hepatocellular Carcinoma (Figure 2)

What are the appropriate criteria for selecting hepatocellular carcinoma treatments?

Recommendations

“Evidence-Based Treatment Algorithm for Hepatocellular Carcinoma” (**Figure 2**) is the recommended selection criteria for treating hepatocellular carcinoma according to the disease state (**Grade B**).

Scientific Statement

An algorithm for treating hepatocellular carcinoma was designed on the basis of three factors: degree of liver damage, number of tumors, and diameter of tumors. The following procedures are recommended for patients with Liver damage A or B liver disease. First, if there is only one tumor, regardless of the tumor diameter, liver resection is the first choice of treatment. However, if the tumor diameter is 3 cm or lesser, radiofrequency ablation (RFA) may also be selected as the second choice (LF00178¹) Level 2b, L3F05892²) Level 2a). Second, if there are two or three tumors with a diameter of 3 cm or lesser, liver resection or RFA is recommended (LF00178¹) Level 2b, L3F05892²) Level 2a). Third, if there are two or three tumors with a diameter of greater than 3 cm, then liver resection is the first choice for treatment and transcatheter arterial

embolization is the second choice (LF06283³) Level 1b). Fourth, if there are four or more tumors, the first choice for treatment is transcatheter arterial embolization and the second choice is systemic chemotherapy including hepatic arterial injection and oral administration (LF06283³) Level 1b, LF10033⁴) Level 3, LF12054⁵) Level 1b). The procedures for patients with liver damage C liver disease are as follows. First, liver transplantation is recommended if there are three or fewer tumors with a diameter of 3 cm or lesser (or if there is a single tumor and the tumor diameter is 5 cm or lesser) and if the patient is 65 years of age or younger (LF00540⁶) Level 2b, LF12128⁷) Level 2b). Second, palliative care is recommended if there are four or more tumors. Patients with Child–Pugh class A liver disease and vascular invasion, however, are occasionally treated with liver resection, chemotherapy, or transcatheter arterial embolization. In addition, systemic chemotherapy is recommended for Child–Pugh class A disease with extrahepatic metastasis (LF12054⁵) Level 1b).

Explanation

Liver resection and RFA were selected for liver damage A and B liver disease on the basis of an article by Arii et al. that compiled data from national follow-up studies conducted by the Liver Cancer Study Group of Japan (LF00178¹) Level 2b) and an article by Hasegawa et al. (L3F05892²) Level 2a). Hasegawa et al. analyzed 2,857 liver resections, 3,022 RFAs, and 1,306 percutaneous ethanol injections administered between 2000 and 2003 to patients with hepatocellular carcinoma who presented with three or fewer tumors measuring 3 cm or lesser in diameter. In addition, although the study extended beyond the time frame of our search, prognostic analysis according to the severity of liver damage, number of tumors, diameter of tumors, and treatment method was performed for 12,968 patients who began treatment between 2000 and 2005 (Level 2a⁸). According to the results, liver resection yielded significantly better results for patients with a single liver damage A or B lesion, and no significant difference was observed in the survival rate between patients with two to three tumors measuring 3 cm or lesser in diameter who underwent liver resection and those who underwent RFA. Transcatheter arterial

embolization was adopted on the basis of a randomized controlled trial (RCT) conducted by Llovet et al., who proved that prognoses were significantly improved in patients with multiple Child–Pugh class A or B lesions (LF06283³) Level 1b). The rationale for using Sorafenib in patients who did not respond to embolization therapy and patients with extrahepatic metastases was based on an RCT (LF12054⁵) Level 1b) that demonstrated the efficacy of Sorafenib. In principle, it is recommended that the degree of liver damage be used in the presented algorithm; however, the Child–Pugh class may also be applied if nonsurgical treatment is considered. Liver transplantation was recommended on the basis of a prospective cohort study conducted by Mazzaferro et al. that proposed the use of the Milan criteria (LF00540⁶) Level 2b) and an article published by Todo et al. that investigated living donor liver transplantation in Japan (LF12128⁷) Level 2b). Two RCTs comparing liver resection and RFA were reported (L3F05846⁹) Level 1b, L3F04414¹⁰) Level 1b). However, because there were problems with research design in both studies, they could not be used as references.

Figure 2: Evidence-based algorithm for the treatment of hepatocellular carcinoma (separate file)

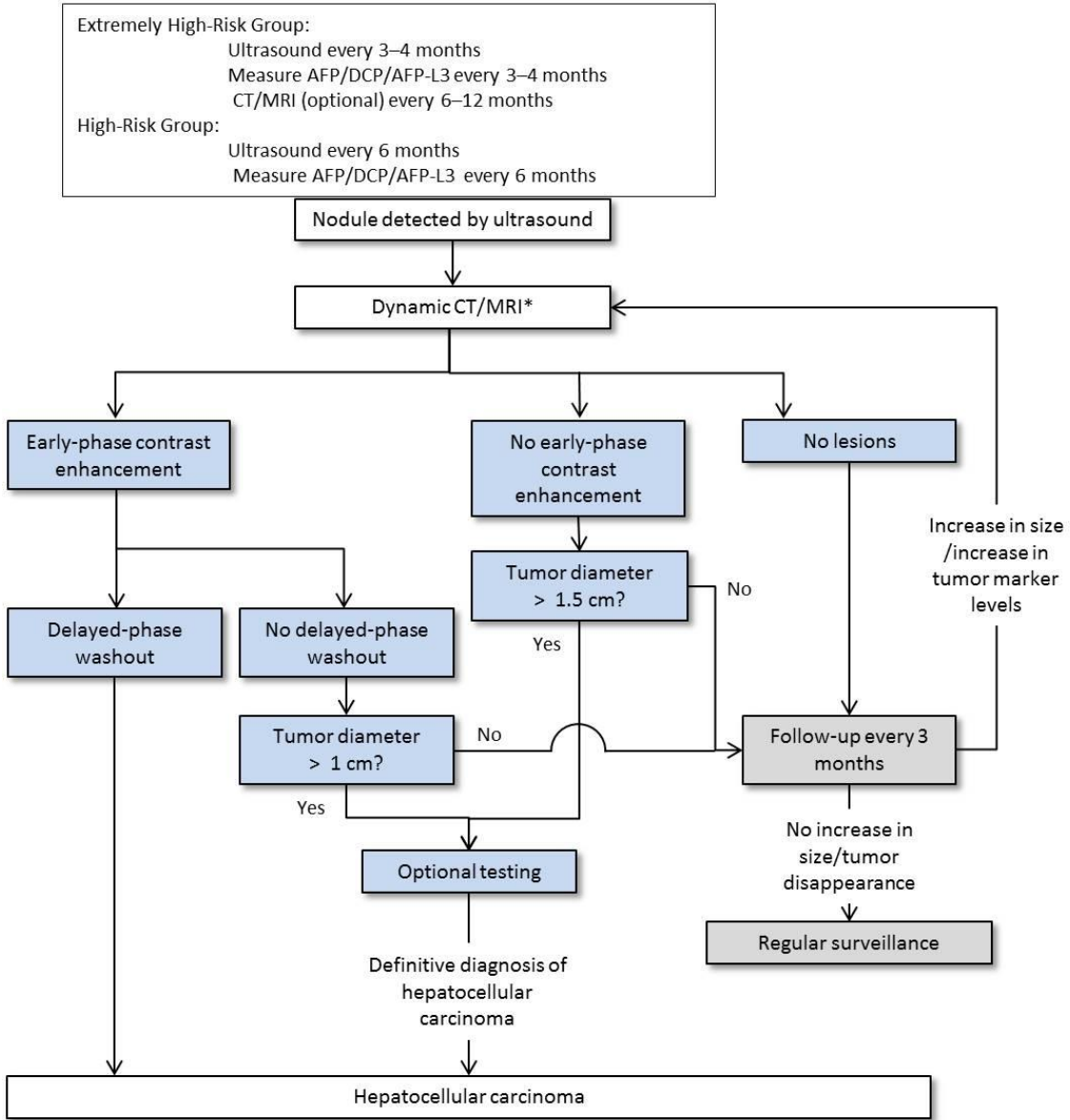
References

- 1) LF00178 Arii S, Yamaoka Y, Futagawa S, Inoue K, Kobayashi K, Kojiro M, et al. Results of surgical and nonsurgical treatment for small-sized hepatocellular carcinomas: a retrospective and nationwide survey in Japan. The Liver Cancer Study Group of Japan. *Hepatology* 2000;32(6):1224-9.
- 2) L3F05892 Hasegawa K, Makuuchi M, Takayama T, Kokudo N, Arii S, Okazaki M, et al. Surgical resection vs. percutaneous ablation for hepatocellular carcinoma : a preliminary report of the Japanese nationwide survey. *J Hepatol* 2008;49(4):589-94.
- 3) LF06283 Llovet JM, Real MI, Montana X, Planas R, Coll S, Aponte J, et al; Barcelona Liver Cancer Group. Arterial embolisation or chemoembolisation versus symptomatic

treatment in patients with unresectable hepatocellular carcinoma : a randomised controlled trial.
Lancet 2002;359(9319):1734-9.

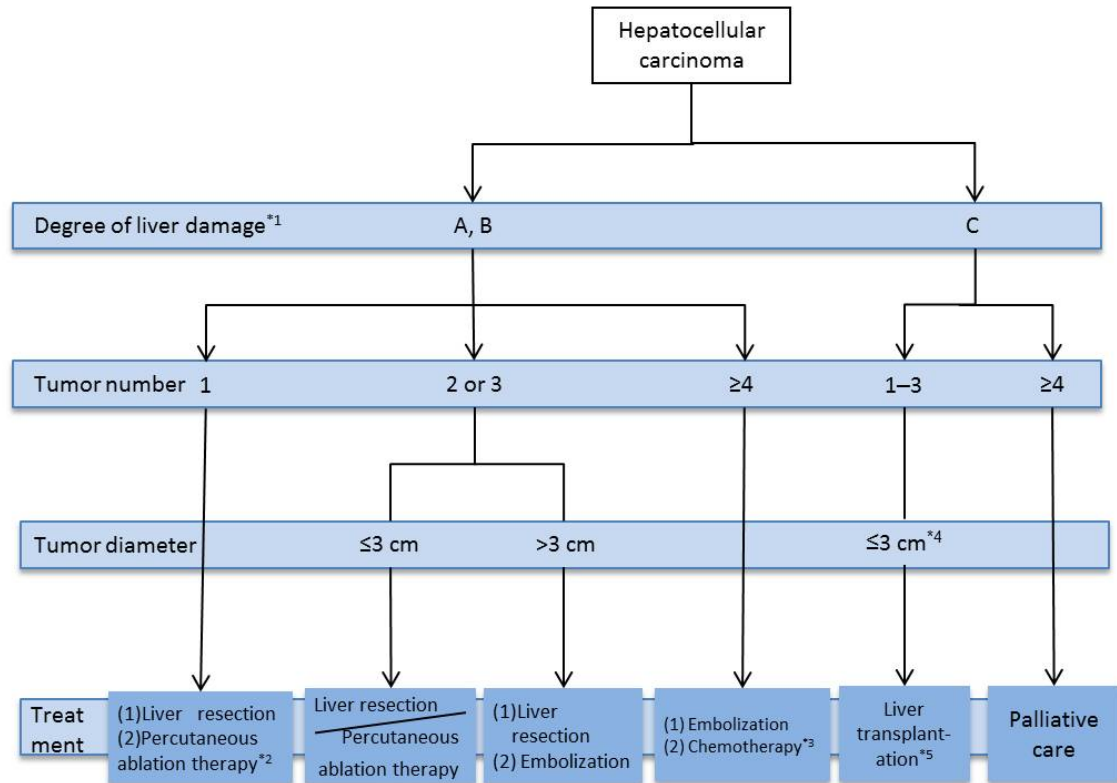
- 4) LF10033 Sumie S, Yamashita F, Ando E, Tanaka M, Yano Y, Fukumori K, et al.
Interventional radiology for advanced hepatocellular carcinoma: comparison of hepatic artery infusion chemotherapy and transcatheter arterial lipiodol chemoembolization. AJR Am J Roentgenol 2003;181(5):1327-34.
- 5) LF12054 Llovet JM, Ricci S, Mazzaferro V, Hilgard P, Gane E, Blanc JF, et al; SHARP Investigators Study Group. Sorafenib in advanced hepatocellular carcinoma. N Engl J Med 2008;359(4):378-90.
- 6) LF00540 Mazzaferro V, Regalia E, Doci R, Andreola S, Pulvirenti A, Bozzetti F, et al. Liver transplantation for the treatment of small hepatocellular carcinomas in patients with cirrhosis. N Engl J Med 1996;334(11):693-9.
- 7) LF12128 Todo S, Furukawa H, Tada M; Japanese Liver Transplantation Study Group.
Extending indication: role of living donor liver transplantation for hepatocellular carcinoma. Liver Transpl 2007; 13 (11 Suppl 2):S48-54.
- 8) Hasegawa K, Kokudo N, Makuuchi M, Izumi N, Ichida T, Kudo M, et al. Comparison of resection and ablation for hepatocellular carcinoma: A cohort study based on a Japanese nationwide survey. J Hepatol 2013;58(4):724-9.
- 9) L3F05846 Huang J, Yan L, Cheng Z, Wu H, Du L, Wang J, et al. A randomized trial comparing radiofrequency ablation and surgical resection for HCC conforming to the Milan criteria. Ann Surg 2010;252(6):903-12.
- 10) L3F04414 Chen MS, Li JQ, Zheng Y, Guo RP, Liang HH, Zhang YQ, et al. A prospective randomized trial comparing percutaneous local ablative therapy and partial hepatectomy for small hepatocellular carcinoma. Ann Surg 2006;243(3):321-8.

Surveillance Algorithm - Diagnostic Algorithm



*CT/MRI are used for some patients even if the nodule(s) are not visualized using ultrasound because of poor visualization capability. Contrast-enhanced ultrasound may be considered for patients with renal impairment and/or allergies to contrast media of CT/MRI.

Treatment Algorithm



PS

- At times, liver resection, chemotherapy, and embolization therapy may be selected for patients with Child–Pugh class A liver damage along with vascular invasion
- Chemotherapy is recommended for patients with Child–Pugh class A disease with extrahepatic metastases.

(Caution) *1: The Child–Pugh classification may also be used when non-surgical treatment is considered.

*2: Can be selected for tumors with a diameter of ≤3 cm.

*3: Oral administration and/or hepatic arterial infusion are available.

*4: A single tumor ≤5cm or 2-3 tumors ≤3cm in diameter

*5: Patients aged ≤ 65 years.